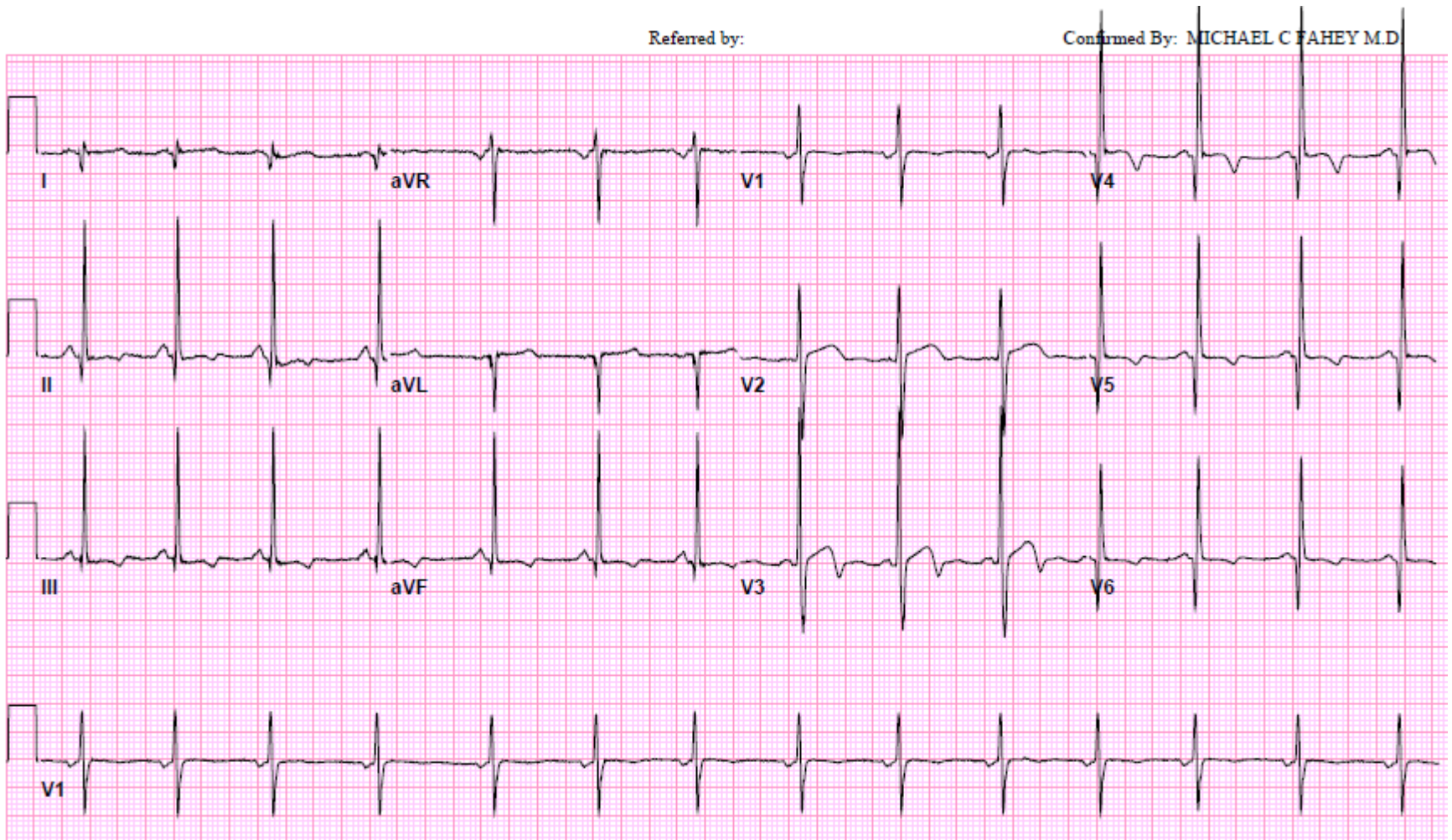


1) How would you read this ECG (2 points)?

2) Given the findings on ECG and the history of a "muscle disorder," what would be your main concern regarding this patient's heart health (1 point)?



- 1) How would you read this ECG (2 points)?
- First, the explanation: There is normal sinus rhythm (upright P waves in leads I and aVF, with a P for every QRS), with a slight right axis deviation that's probably within normal limits (QRS just a little more downward than it is upright in lead I). The P waves in lead II are a touch wide and there is a prominent negative component to the P wave in lead V1, so I would think about left atrial enlargement here but I don't think it meets criteria. There are very deep Q waves in the lateral precordial leads suggestive of LVH. When you see Q waves in the inferior leads or lateral precordial leads that are deeper than 5mm on a full-standard ECG, think LVH. Also note the inverted T waves in the lateral precordial leads. This is a big red flag! When you see this pattern, think cardiomyopathy, LVH, myocarditis, some other sort of myocardial damage, or left ventricular strain (ie, think badness).
- So, the official read is: Normal sinus rhythm. Slight right axis deviation, within normal limits. Left ventricular hypertrophy with strain pattern (also acceptable would be any variation of "LVH with suspected myocardial disease").

- 2) Given the findings on ECG and the history of a "muscle disorder," what would be your main concern regarding this patient's heart health (1 point)?
- The main concern with this patient has to be the development of a cardiomyopathy in the setting of a global muscle disorder (this patient happens to have non-Duchenne's muscular dystrophy).